Efficacy with Autologous Conjunctival Implant Associated with Phototherapeutic Keratectomy (PTK) in the Treatment of the Pterygium

P.F. Fiorini[1], A. Mularoni[1], L. Di Silvestre[1], L. Inferrera[2,*], P. Aragona[2] and A. Meduri[2]

[1]*Department of Ophthalmology, Ospedale Maggiore of Bologna, Italy*

[2]*Department of Ophtalmology, Policlinico Universitario of Messina, Italy*

Abstract: *Purpose*: To evaluate the efficacy of new formula of the PTK calculated with the head-limbus-distance (=height) and limbal base length of the pterygium and ablation thickness on the anterior corneal curvature and visual acuity, associated with autologous conjuntival implant in patients with primary (Group A)and secondary(Group B) pterygium.

Setting: This study was developed in the Department of Ophthalmology, Maggiore Hospital of Bologna.

Design: Prospective non randomized study was conducted in 18 eyes of 18 subjects (9 eyes primary and 9 eyes with recurrent pterygium) operated with a dedicated PTK program.

Methods: All patients signed informed consent before the start of the research. BCVA (Best Corrected Visual Acuity), mean refractive error (ME) and topographic astigmatism and recurrence of pterygium was followed. Mean follow up was 18.67 ± 6.13 months Min: 12 Max: 24 months.

Results: Mean post-operative BCVA increased at 3-24 months compared with pre-op BCVA (p= 0.003). Mean post-op BCVA improved independent of the optical zone involvement in the pre-op (p= 0.845).

Mean Pre-op astigmatism (Group A): was: 0,97 ± 2,7 (MIN: -2,8 Max: +5). Mean pre-op Astigmatism (Group B) :-0,33 ± 1,98 (MIN: -3 Max:+4). Astigmatism reduction in the group A: 0 D; Group B: -0,1D ± 0,74D MIN: -1 Max: +1. No statistically difference at 24 months from two groups in BCVA (p=0,59), Sf (P=0,7), ME(p=0,7), astigmatism (p=0,96) ANOVA. Recurrence of pterygium was: 0%.

Conclusions: The dedicated programme of PTK was shown to be safe and effective for the treatment of the pterygium. BCVA can be improved by providing a smooth corneal surface in cases of optical zone involvement.

Keywords: Pterygium, Treatment-PTK, Phototherapeutic Keratectomy.

INTRODUCTION

Pterygia are wing-shaped interpalpebral masses that emanate from the interpalpebral bulbar conjunctiva and limbus with head migrating onto the cornea, involving Bowmans membrane and superficial anterior corneal stroma, usually on the nasal side [1] (Table **1**).

The limbal theory suggested a deregulation in the barrier maintaining of the limbus with start of conjunctival proliferative process [2].

Pterygia may cause topographic changes and increase astigmatism through a resultant vector of the traction forces originated from the height and the base of the pterygium.

Surgical treatment of pterygium is directed at excision, prevention of recurrence, and restoration of ocular surface integrity.

The excision of the pterygium with simple conjunctival closure conduced to a lot numbers of the pterygium recurrence rates (80%) which may be more aggressive than the primary process [3].

The excision together with adjunctive therapies such as radiotherapy, mitomycin and 5FU will reduce the 80% of the recurrence of the simple excision to about 10% [4].

The surgical techniques, some combined with others, have been described for reduced the recurrence rate and carried to 5-10% (bare sclera excision, excision with conjunctival autograft or amniotic membrane transplantation, narrow strip conjunctival autograft) [5].

MATERIALS AND METHODS

Prospective non randomized study was conduced in 18 eyes of 18 subjects (9 eyes primary pterygium and 9 eyes with recurrent pterygium) operated with a dedicaded PTK program by iRes technology laser system (LIGI Technology – Italy) by one surgeon.

*Address correspondence to this author at the Via Sal. Contino lotto F pal. 21 Me 2, 98124 Messina, Italy; Tel: +393466846758;
E-mail: inferreraleandro@gmail.com, ameduri@unime.it

E-ISSN: 2309-6136/17

Table 1: Morfology of the Pterygium

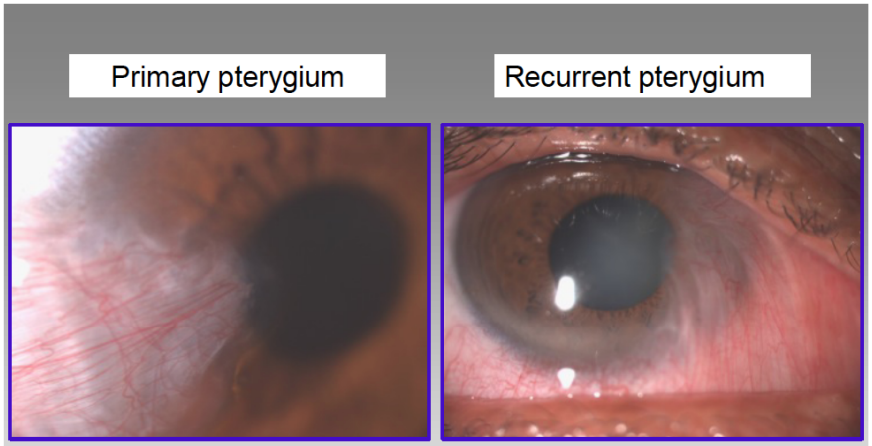

Tipe of pterygium	Primary	Recurrent
Time of resse	+	+++
Corneal involvement	+	++
Flare	+	++++
Fibrovascular tissue	++	++++
Sintome	+	+++

Table 2: PTK Customized Programm

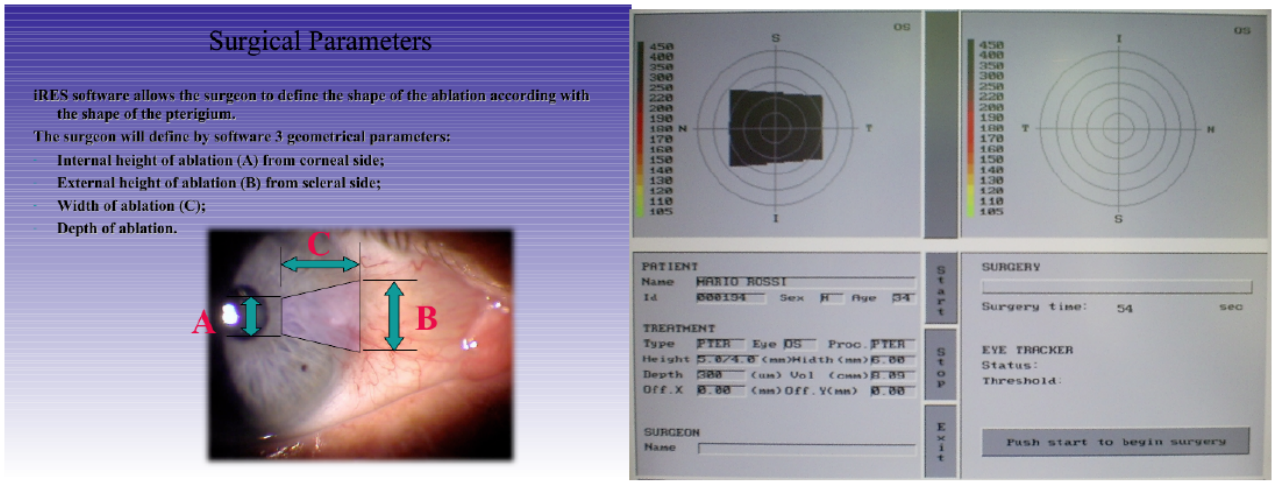

IRES is the first refractive laser system specifically developed to perform customized refractive and therapeutic corneal surgeries. Surgical computer-aided design and planning using the principles of CIPTA ™ (Corneal Interactive Programmed Topographic Ablation) and CLAT ™ (Corneal Lamellar Ablation for Transplantation), integrates the real corneal shape, dynamic pupil assessment, and refractive aberrations to define the ablation profile.

The Technology Characteristics

IRES eyetracker (iTRK) monitor displays infrared surgical view. Industry leading, ultrafast 1,000 HZ (dual beam@500Hz), high resolution, micrometric 0.6mm dual gaussian spot laser, total processes automation, including machine vision, objective, self-calibration.

Unique to iVIS, the iRES laser utilizes Constant Frequency per Area™, Variable Width, Constant Slope™ transition zones, and High Definition Delivery ™ to implement a new standard of quality for custom refractive and therapeutic applications.

IRES software allows the surgeon to define the shape of ablation according with the shape of the pterigium (Table **2**).

The surgeon will define by software 3 geometrical parameters:

1. internal height of ablation (A) from corneal side

2. external height of ablation (B) from scleral side

3. width of ablation (C)

The type of pterygium at the time of the surgery were divided in primary (Group A) 50% of cases (9 patients), and recurrent pterygium (Group B) 50% of cases (27,78% with one recurrence, 5,56% with 2 recurrence, 11,11% with 3 recurrence, 5,56% with 4 recurrence) (Table **3**).

Table 3: Tipe of pterygium at the time of the surgery were divided in primary 50% of cases (9 pz), and recurrent pterygium 50% of cases (27,78% with one recurrence, 5,56% with 2 recurrence, 11,11% with 3 recurrence, 5,56% with 4 recurrence)

Pterygium Morphology

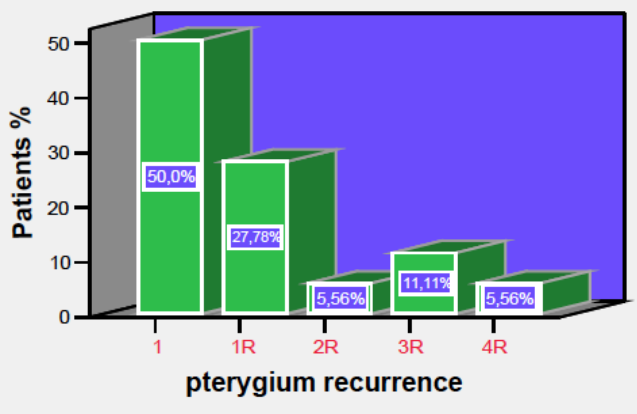

Mean deviation of the age of the patients of surgery was 56.11 years, and standard deviation was 20.19 (Min: 31 Max: 85 years old).Nine of 18 patients (50%) were female, and 9 patients (50%) were male.

The BCVA, refractive and topographic astigmatism and recurrence of pterygium was detected.

Mean deviation of follow up was 18.67 and the standard deviation was (SD) 6.13 months (Min: 12 Max: 24 months).

Postoperative examinations were performed at approximately 1, 7, 30 days, then again 6, 12, and 24 months.

Surgical indications were: impediment or manifest visual loss, optical zone involvement, irregular astigmatism, symptomatic pterygium, ocular motility restriction.

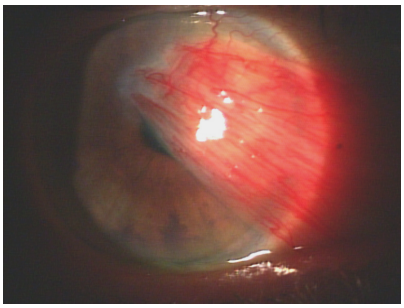

Figure 1: Preoperative case: Pterygium with a optic zone involvement.

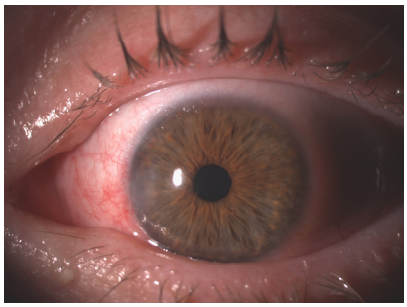

Figure 2: Postoperative case: 7 days.

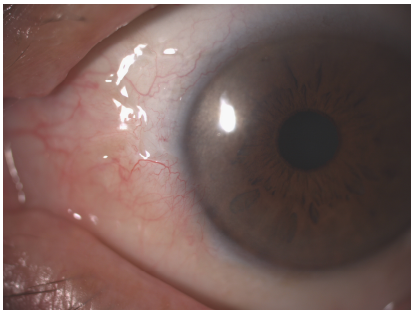

Figure 3: Postoperative case: 15 days.

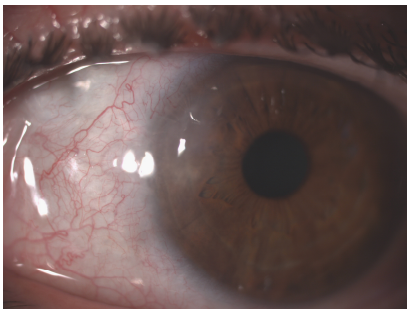

Figure 4: Postoperative case: 24 months.

Exclusion Criteria: Symblepharon

The surgical technique used was based on the described by Kenyon and collaborators [6] with the only difference being inclusion of the limbus in the conjunctival autograft.

The operations were performed under retrobulbar anaesthesia with 2% lidocaine and 0.5% ropivacaina

10 mg/ml. The area of surgery is sterilised with appropriate antiseptic (Betadine, Texas, USA) and by surgical draping. After irrigating the conjunctiva with copious amounts of balanced salt solution, the head of the pterygium with its cap is dissected off the cornea with a bevel-up micro blade in a peeling action. The blunt posterior surface of the needle's bevel can reliably follow the corneal curvature. The pterygium is dissected from the cornea with the micro blade held tangentially to the cornea and with a horizontal scraping action, raising the abnormal tissue off the Bowman's layer in a lamellar fashion. The pterygial tissue and the conjunctiva with a large amount of fibrous-subconjunctival tissue are excised; in the 22% of case in which there was a preexisting restriction of ocular motility, the fibrovascular tissue was removed even around the medial rectus muscle till it was released and in 6% of cases inferior rectus muscle involvement (Table **4**). After application of viscous masking and wetting solution of sodium hyaluronate 0,25% (Laservis, TRB Chemedica), PTK was performed calculated with the head-limbus-distance (=height) and limbal base length of the pterygium and ablation thickness on the anterior corneal curvature to create a uniform plane on corneal bed (Table **2**).

Table 4: Tipe of surgery

PTK: Photorefractive Keratectomy

AI: Autologous conjuntival implant

RM: Medial Rectus muscle

RI: Inferior Rectus muscle

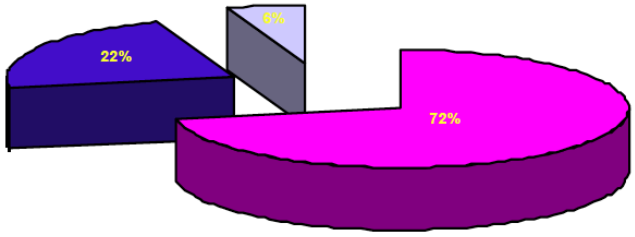

The size of the bare scleral bed and the graft area are measured with Castroviejo calipers (Bausch & Lomb Storz, Storz Instruments, MO, USA). The excision graft area was marked with a gentian violet marked pen. Starting from one of the four corners of the delimited area, using a 5.0ml syringe, air is inject into the conjunctival layers, trying keeping the 30G needle as superficial as possible in order to separate the conjunctiva from the underlying submucosa. Then, after making a small incision with a blade, the graft is dissected with blunt scissor (Westcott). The resected conjunctival graft may be slid over the cornea, oriented limbal border to limbus. The autograft is sutured into position neighbouring conjunctiva using sutures or 8-0 Vicryl (ETHICON) in a simple interrupted fashion or fibrin glue Tissucol 1,0 ml (Tissucol Duo, BAXTER).

Fibrin glue is a biological tissue adhesive which initiates the final stages of coagulation when a solution of the human fibrinogen is activated by thrombin (the 2 components of fibrin glue).

Application of a contact lens is used for comfort and to facilitate the corneal reepithelialization.

RESULTS

Efficacy of PTK Associated Autologous Autograft Thecnique

Mean post-operative BCVA increased at 3 months and 1 at 6, 12, and 24 months (0,85 ±0,21 SD) statistically difference with pre-op BCVA (0,75 ±0,25) (p= 0.003) (T-test) (Table **5**).

Table 5: Mean post-operative BCVA increased at 3 months and 1 at 6, 12, and 24 months (0.85±0.21) statistically difference with pre-op BCVA (0.75±0.25) (p=0.003) (T-test)

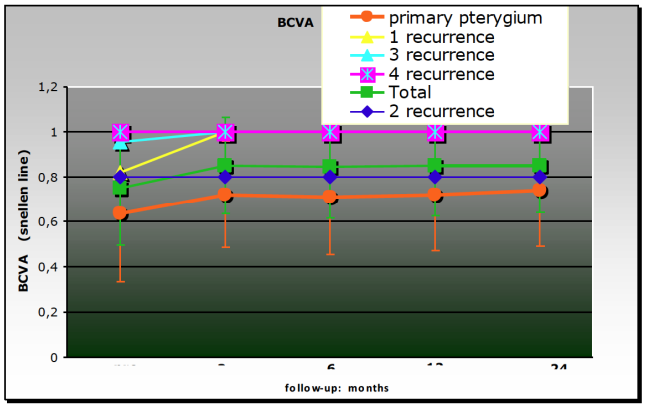

Mean post-op BCVA improved independent from the optical zone involvement in the pre-op (p= 0.845) (T-test) (Table **6**).

Best-corrected visual acuity (BCVA) and optic zone of the pterygium correlated significantly inversely (p=0.001).

Visual acuity seemed to be mostly unaffected up to a height of 2.5 mm. Overall, the impact of the base length was much less striking.

Table 6: BCVA and optic zone correlation. Mean post-op BCVA improved indipendent from the optical zone involvement in the pre-op (p=0.845) (T-test)

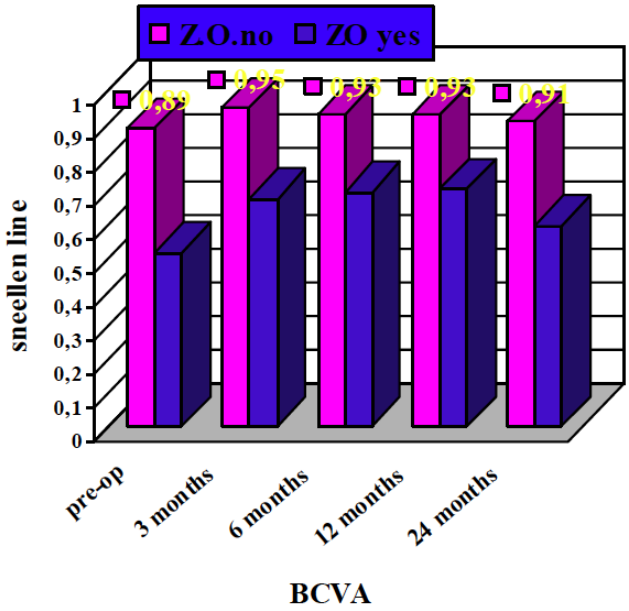

Mean Preoperative astigmatism in the Group A: was: 0,97 diopters and the stand deviation was± 2,7 diopters (D) (MIN: -2,8 Max: +5).

Mean preoperative Astigmatism in the Group B was -0,33 D ± 1,98 (SD) (MIN: -3 Max: +4).

Mean postoperative astigmatism in the Group A at 24 months was: 0 ± 0 (MIN: 0 Max: 0).

Mean postoperative astigmatism in the group B at 24 months was: -0,1 ± 0,74 D (MIN: -1 Max: +1) (Table **7**).

Table 7: Refractive astigmatism pre operative and post operative at 3-6-12-24 months in primary and recurrent pterygium

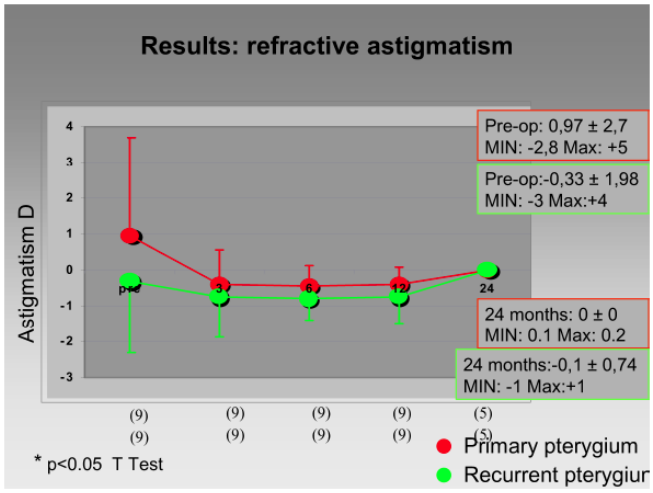

Astigmatism reduction in the group A was: 0 diopter; Group B: -0,1D ± 0,74D MIN: -1 Max:+1. No statistically difference was detected at 24 months from two groups in BCVA (p=0,59), Sf (P=0,7), ME (p=0,7), astigmatism (p=0,96) ANOVA (Table **8**).

Table 8: Mean refractive error (ME) pre operative and post operative at 3-6-12-24 months in primary and recurrent pterygium

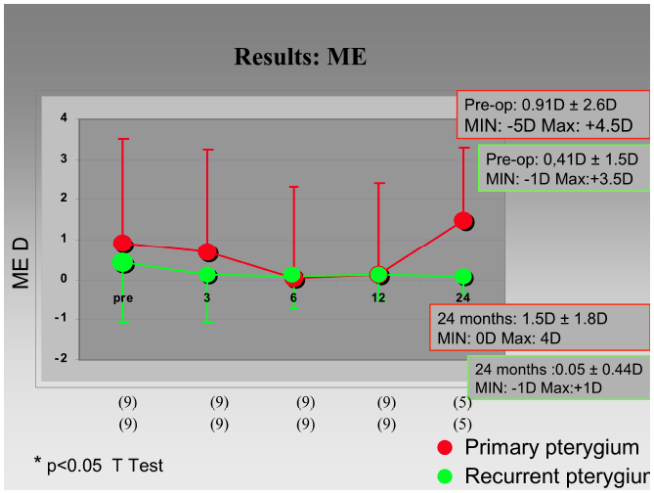

Recurrence of pterygium was: 0%.

(Statistical data SPSS 3.1 version for Windows)

DISCUSSION

The PTK dedicated programme was effective and safe in creating a smooth surface in cases of optical zone involvement with ablating the visible residual tissue in the visual axis and even in the peripheral cornea.

The constant pulse rate per area of the spot laser produced a regular corneal layer ablation with a regularization of the pterygium area (Table **9-10**).

Table 9: Preoperative TOPOGRAPHY

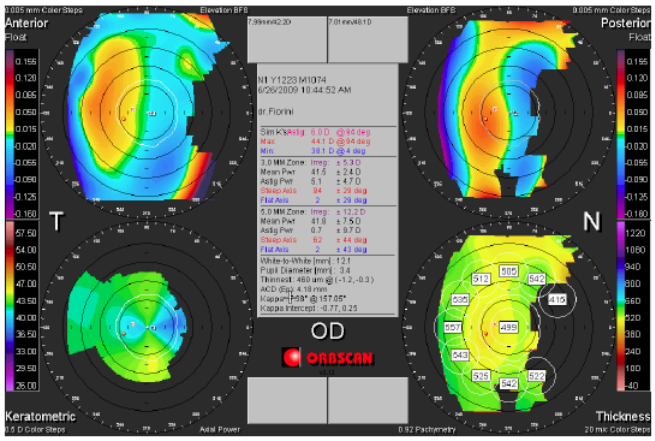

Table 10: Post-operative 4 months TOPOGRAPHY

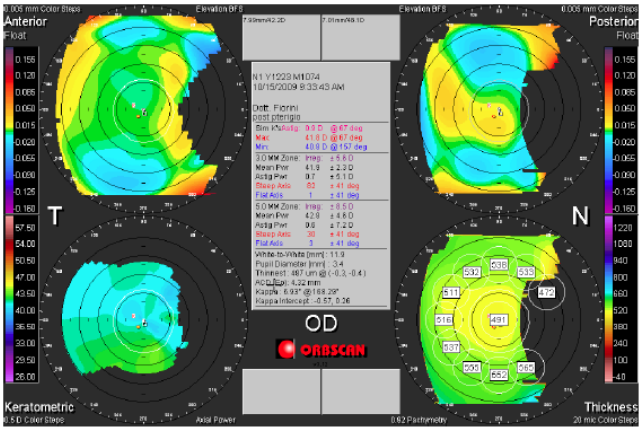

A smooth corneal area created a regular distribution of the lacrimal film reducing the inflammatory reaction.

This is one cause of the pterygium recurrence.

The effect of the pterygium morphology on corneal astigmatism was not significant, the regularization of the optic zone occurred although the optic zone involvement of the pterygium and surgery recurrences.

The astigmatism and the mean refractive error reduction improve the quality of vision.

The extinction of the grip vectorial force of the pterygium onto corneal surface reduce the vision aberrations.

The correct graft orientation was made limbus-limbus and fornix fornix (no necrosis of the graft) [7]. In the early post-operative period, the limbal-fornix disorientation of the conjunctival graft produced oedema of the tissue [7-8].

Also the failure of the conjunctival graft can occur after graft inversion because of mucosal conctact with the avascular sclera [9].

The injection of the air, just beneath conjunctival surface, was harvested as thin as conjunctival graft as possible. In fact a regular conjunctival bed prevents the risk of complications such as granuloma formation [10]

The dissection of the Tenon's capsule as well as the receiving bed is important (to prevent sliding of the conjunctiva onto the cornea).

The reepithelialization on the site of donor conjuntiva in safety and regular (no granulomatous reaction); with air technique dissection, the graft is thinner, linking to the underlying and surrounding tissue better.

It is possible that the epithelium emanating from the graft is different and likely and healthier than that originating from the conjunctival wound at the cut edge of the pterygium. In our study the residual pterygium tissue seemed not to violate the zone created with PTK customized ablation.

We recommend using the Tissucol separately (a component on the back of the graft and the other on the sclera) to allow time to place the graft. Tissucol permits a safe conjunctival adhesion for pterygium autograft surgery.

Because of its fast and easy application, this product reduces the time of surgery, the complication of the sutures and foreign body sensation [10]

Recurrence of pterygium is the most common complication of pterygium surgery. Although recurrence rates are reduced with this technique. The conjunctival autograft was effective in reducing the pterygium recurrence.

CONCLUSIONS

This thecnique permited a refractive and durable results in a treatment of the pterygium. The personalizated PTK programm improve the quality of vision. The conjunctival autograft provides for preservation of the limbal stem cells. The fibrine glue decreased the operating time and the postoperative discomfort. The dedicated programme of PTK was shown to be safe and effective for the treatment of the pterygium.

REFERENCE

[1] Hirst Lw. The treatment of pterygium. Surv Ophthalmol 2003: 48: 145-80. https://doi.org/10.1016/S0039-6257(02)00463-0

[2] Dushku N., Reid TW. Immunohistochemical evidence that human pterygia originate from an invasion of vimentin-espressing altered limbal epithelial basal cells. Curr. Eye Res. 1994; 13, 473-481. https://doi.org/10.3109/02713689408999878

[3] Hirst LW. Mitomycin C in the treatment of the pterygium. Clin Experiment Ophthalmol. 2006 Apr; 34(3): 197-8. https://doi.org/10.1111/j.1442-9071.2006.01195.x

[4] King JH Jr. The pterygium: brief review and evaluation of certain methods of treatment. AMA Arch Ophthalmol 1950; 44: 854-69. https://doi.org/10.1001/archopht.1950.00910020867008

[5] Dupps WJ Jr, Jeng BH, Meisler DM. Narrow-strip conjunctival autograft for treatment of pterygium. Ophthalmology. 2007 Feb; 114(2): 227-31. Epub 2006 Nov 30. https://doi.org/10.1016/j.ophtha.2006.08.040

[6] Kenyon KR, Wagoner MD, Hettinger ME. Conjunctival autograft transplantation for advanced and recurrent pterygium. Ophthalmology 1985; 92: 1461-70. https://doi.org/10.1016/S0161-6420(85)33831-9

[7] Stark T, Kenyon KR, Serrano F. Conjuntival autograft for primary and recurrent pterygia: surgical technique and problem management. Cornea 1991; 10: 196-202. https://doi.org/10.1097/00003226-199105000-00002

[8] EC Figueira, MT Coroneo and IC Francis. Preventing conjunctival autograft inversion in pterygium surgery. Br J Ophthalmol. 2007 jan; 91(1): 83-4. https://doi.org/10.1136/bjo.2006.102905

[9] Rocha G. Surgical management of pterygium. Tech Ophthalmol 2003; 1: 22-8. https://doi.org/10.1097/00145756-200303000-00008

[10] A Karalezli, C Kucukerdonmez, YA Akova, R Altan-Yaycioglu, M BorazanFibrin glue versus sutures for conjunctival autografting in pterygium surgery: a prospective comparative study B J of Ophthalmology 2008; 92: 1206-1210.

Received on 25-05-2017 Accepted on 07-07-2017 Published on 23-10-2017

DOI: https://doi.org/10.12974/2309-6136.2017.05.03