

Refractive Surgical Problem

Edited by Sonia H. Yoo, MD

A 27-year-old woman presents for consultation for poor quality of vision. She has a history of bilateral myopic laser in situ keratomileusis (LASIK) performed 3 years previously by another surgeon for correction of -4.75 diopters in both eyes. The patient reports that during her LASIK surgery, “her corneal flaps were incomplete.”

The ophthalmologic examination shows an uncorrected visual acuity (UCVA) of 20/40 and a best spectacle-corrected visual acuity (BSCVA) of 20/25 in both eyes. The manifest refraction is plano $+1.25 \times 170$ in the right eye and $-1.00 +1.00 \times 180$ in the left eye. The slitlamp examination shows a corneal stromal scar consistent with a flap hinge that approaches the visual axis in both eyes (Figure 1). Evaluation of the posterior segment and intraocular pressure were normal. Scheimpflug images (Pentacam, Oculus) and corneal topography are shown in Figure 2 and Figure 3, respectively.

Would you perform another examination(s)? Would you treat both eyes? If yes, what would be the best approach?

■ This post-LASIK patient faces 2 main problems. The first is the residual refractive error (hyperopic astigmatism) and the second, poor vision quality. Both problems are mainly caused by incomplete flap

creation during LASIK. The surgeon did not abort the procedure and decided to proceed with the ablation (probably by covering the hinge position).

I would perform 5 additional examinations. The first would be to determine the scotopic pupil size to adjust the new treatment zone for retreatment. Second would be a dominant-eye examination. Third would be a hard contact lens overrefraction to determine whether there is loss of best corrected visual acuity as a result of irregular astigmatism or scar formation. Fourth would be anterior segment optical coherence tomography (AS-OCT) for flap and residual corneal bed thickness estimation to establish whether there is additional thickness for retreatment. Fifth would be wavefront measurement to assess higher-order aberrations (HOAs).

After receiving the information from the examinations, my first treatment choice would be bilateral LASIK retreatment after flap creation using a mechanical microkeratome with a deeper depth plate and the AS-OCT measurement of the previous flap thickness. I would use a mechanical microkeratome because femtosecond lasers increase the risk for flap complications in eyes with scarred corneas.

Another crucial issue is whether the residual corneal bed thickness (determined by AS-OCT) is adequate to perform the ablation. If the thickness were not

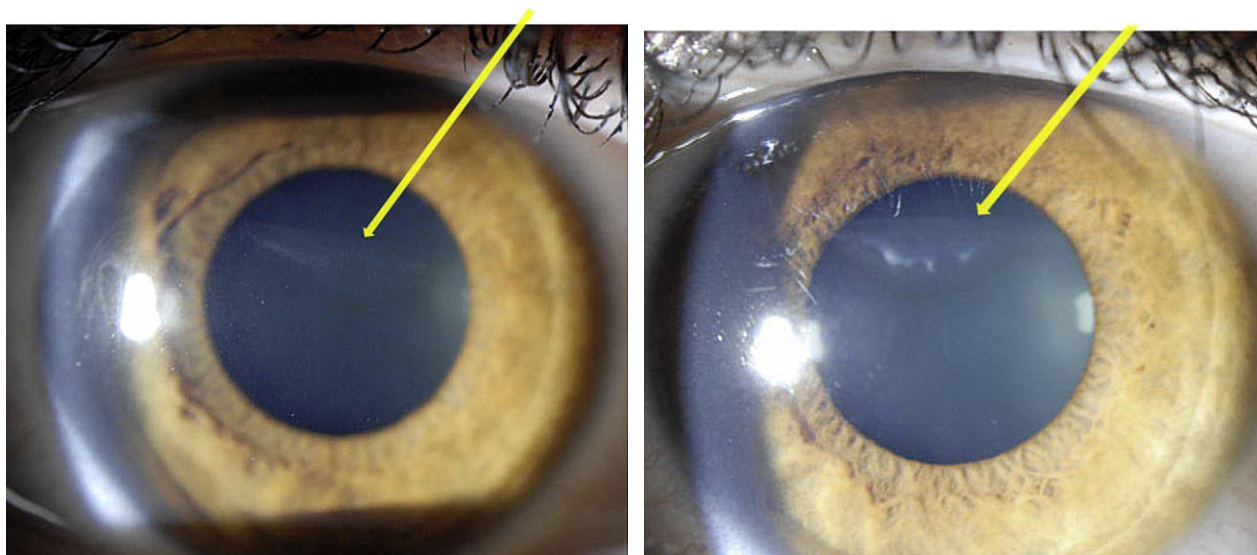


Figure 1. Flap hinge within visual axis in the right eye (left) and the left eye (right).

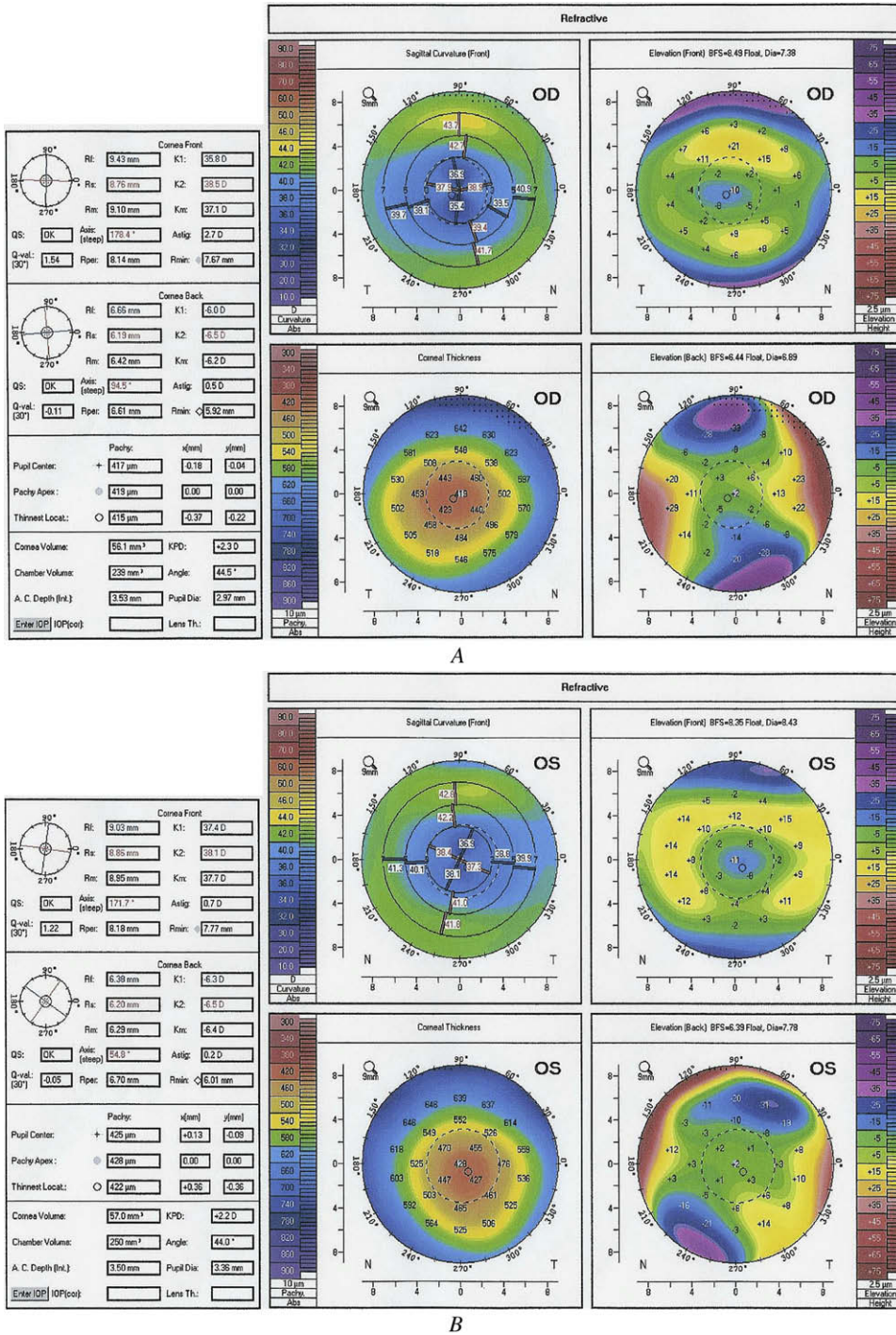


Figure 2. Scheimpflug images of the right eye (A) and left eye (B).

prohibitive, my choice would be to treat the residual astigmatism with a topography-guided ablation to enlarge the optical zone and decrease HOAs. If there were not adequate residual corneal bed thicknesses for re-treatment, my choice would be topography-guided photorefractive keratectomy (PRK) with mitomycin-C (MMC) 0.02% for 30 seconds. Specifically, in this patient, I would remove the epithelium using phototherapeutic keratectomy (PTK) for 50 μm.

The major problem with this approach is that the ablation rate is different in areas with scars while the postoperative wound-healing process is not well controlled, as with LASIK. For these reasons, my approach would be unilateral, starting with the non-dominant eye.

George D. Kymionis, MD, PhD
Heraklion, Greece

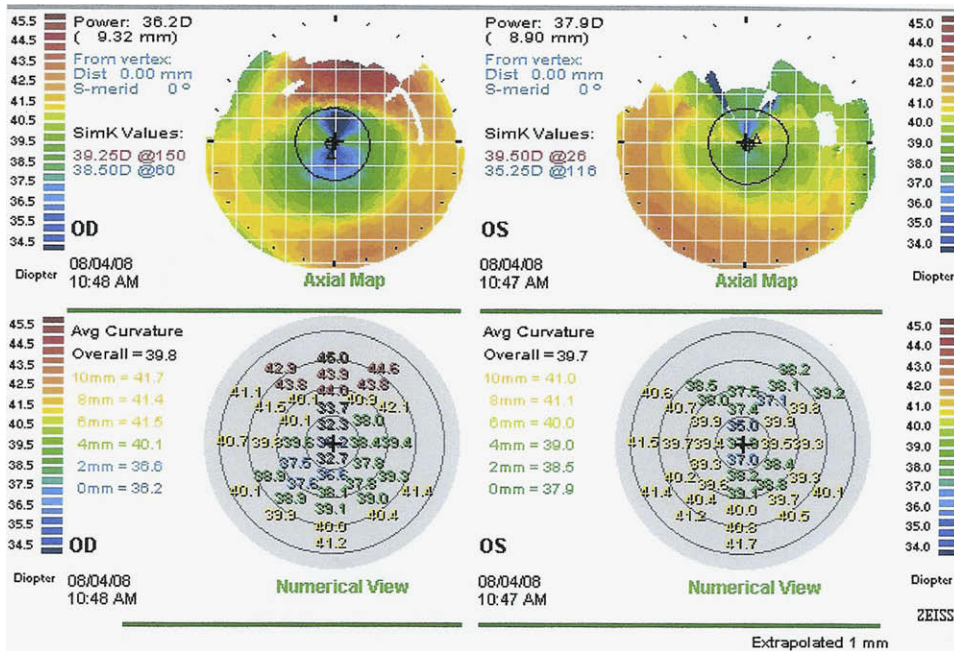


Figure 3. Corneal topography.

■ The patient had bilateral LASIK for moderate myopia, complicated by incomplete flaps. It resulted in decreased visual acuity and poor quality of vision in both eyes. On examination 3 years later, the BSCVA in both eyes is 20/25, with 1.00 D of against-the-rule astigmatism.

The slitlamp photographs of both eyes show a corneal stromal scar consistent with a superior LASIK-flap hinge well within the pupillary area. The topography shows asymmetric corneal optics and a small ablation zone. The Scheimpflug images confirm the small ablation zone, while the configuration of the posterior surface and the pachymetry map do not raise concern of compromised corneal biomechanical stability. The thinnest point in both eyes is approximately 420 μ m.

The patient's poor quality of vision can be explained by irregular astigmatism (caused by asymmetric optics), a small optical zone, and possibly a decrease in transparency and/or scattering (caused by the scar at the flap hinge). A very-high-frequency digital ultrasound scan (Artemis, ArcScan Inc.) or high-definition corneal OCT would be crucial in this case for precise mapping of the thickness of the flap and the depth of the scar.

Wavefront aberrometry may be useful in confirming the effect of the irregular astigmatism and the small optical zone. It may also give an estimate of the correlation between the amount of HOAs and the patient's symptoms of decreased quality of vision. If the symptoms of poor quality of vision cannot be explained by the amount of HOAs, they might have originated from the decrease in transparency, the scattering, or both. In

addition, a hard contact lens trial would help determine the magnitude of influence of the transparency and scattering on the subjective quality of vision by temporarily reducing the HOAs originating from the corneal surface.

Regarding treatment, the goal should be to improve the quality of vision by regularizing the irregular corneal optics, removing the scar (if shown to be a source of transparency decrease/scattering), and correcting the residual spherocylinder. A conservative approach with gas-permeable hard contact lenses should be considered. If this approach were not acceptable to the patient, topography-guided surface custom ablation on top of the flap seems to be the most attractive and safest option. Custom ablation with a relief is not an option because of the "short" flap with superior hinge inside the pupillary area. Not only would a flap recut be risky because of the relatively thin cornea, it would by no means address the issue of scars within the optical area. If the decreased transparency/scattering is indeed a part of the reason for the poor quality of vision, a surface topography-guided ablation that includes ablation of the scars should be considered if the scars are superficial enough. If we also take into consideration that significant epithelial remodeling likely occurred in this case, any approach in which the epithelium is simply removed without taking the remodeling effect into account (as in common surface ablation) could result in a significant error and might induce new optical irregularities.

This leaves a transepithelial approach, in which epithelial removal is an integral part of the custom

ablation, as our best option. I have successfully treated similar cases with flap or interface irregularities using custom transepithelial no-touch ablation on the iVIS Suite laser system (iVIS Technologies). The patient's refraction; corneal anterior elevation (measured by Scheimpflug topography); pachymetry map; and pupil, iris, and scleral registration information would be imported into the ablation-planning software to design an ablation with the aim of transforming the detected irregular corneal shape into a regularized aspheric shape placed at the specified depth under the pathology that causes visual disturbances. I would not hesitate to use such a technique in this case if the measurements of the depth of the scars confirm that there would be enough corneal tissue for a safe procedure.

Aleksandar Stojanovic, MD

Tromsøe and Oslo, Norway

■ The patient has bilateral irregular astigmatism from incomplete flaps with hinges within the pupil. The patient is symptomatic, and I would first repeat the topographies with a Topolyzer corneal topographer (Alcon) to determine whether I can produce repeatable topographies. If the topographies were reproducible, I would consider retreating the patient with topography-guided PRK. I would treat 1 eye at a time. I would determine eye dominance and treat the nondominant eye first. Repeat procedures are less predictable than primary treatments, so treating 1 eye at a time is more prudent.

The procedure of choice would be transepithelial PRK. This procedure is less disruptive to a previous flap. In addition, one would not risk dislocating a previous flap during manual epithelial removal. This would be followed by a topography-guided treatment linked to the corneal topography used for the repeat topographies. After PRK, I would use MMC 0.02% for 20 seconds followed by copious irrigation. A tapering steroid regimen over 3 months would follow.

I would treat the second eye 6 months after the first eye has stabilized.

David T.C. Lin, FRCSC

Vancouver, Canada

■ This is a case of a 27-year-old woman who reports poor quality of vision after LASIK with incomplete flaps. The Scheimpflug images show that in both eyes, there is a thin, flat cornea in the center and a thick, steeper cornea superiorly. These findings are compatible with the slitlamp examination, which shows a corneal stromal scar consistent with a flap hinge approaching the visual axis in both eyes.

Considering this scenario, the best option would be to perform a corneal wavefront examination followed by corneal wavefront-guided PRK. We would recommend removal of the epithelium with an excimer laser using the PTK mode (depth 45 μm in a 9.0 mm area) or the use of dilute alcohol, in which case the epithelium would have to be extremely loose so that the flap will not accidentally be dislodged during epithelial removal. After epithelial debridement, the corneal wavefront-guided ablation would be applied using the pupil center under mesopic conditions as a reference. After the laser treatment, we would recommend the use of a sponge soaked with MMC 0.02% placed for 12 seconds on the exposed corneal bed followed by abundant irrigation with a balanced salt solution. Finally, a soft contact lens would be placed and maintained until reepithelialization is complete (in 4 to 6 days).

In the postoperative period, we would prescribe aggressive use of topical steroidal drops until the epithelium has healed. This would be useful considering that epithelial defects in LASIK are a risk factor for the development of diffuse lamellar keratitis.

Artur Schmitt, MD

Fernanda Piccoli, MD

Miami, Florida, USA

Curitiba, Parana, Brazil