

RESEARCH

Open Access



Central corneal regularization (CCR): an alternative approach in keratoconus treatment

Giulio Mulè¹, Shihao Chen², Jia Zhang², Wen Zhou³, Vasileios Selimis⁴, Aleksandar Stojanovic³ and Ioannis M. Aslanides^{2,4*}

Abstract

Background: To evaluate the safety and efficacy of an approach that combines corneal customized transepithelial therapeutic ablation to treat irregular corneal optics and accelerated corneal collagen cross-linking (CXL) to strengthen the corneal tissue and stop the progression of keratoconus. The transepithelial therapeutic ablation applied a novel concept named central corneal regularization (CCR) which could correct the corneal morphological irregularities and the eye's spherocylindrical refractive error with minimal stromal tissue removal.

Methods: Retrospective study. Eyes that underwent CCR combined with CXL were evaluated preoperatively and up to 12 months postoperatively for visual acuity, subjective refraction, corneal haze, pachymetry and maximum keratometry (Kmax).

Results: Twenty four eyes of 24 patients with a mean age of 28.92 ± 9.88 years were treated. The mean spherical equivalent (SE) refractive error changed from -0.74 ± 1.17 D preoperatively to -1.05 ± 1.52 D at 12 months postoperatively. The mean uncorrected distance visual acuity (UDVA) and corrected distance visual acuity (CDVA) improved. No eye lost lines of CDVA, 21 had a mean improvement of 3.21 lines. The mean cylinder error and Kmax value dropped from -3.06 ± 1.83 D and 51.38 ± 3.29 D to -1.04 ± 0.80 D and 48.70 ± 2.58 D, respectively. The mean haze score at 3, 6 and 12 months was 0.56, 0.19 and 0.06, respectively.

Conclusions: CCR combined with CXL offers promising results as a safe and effective treatment in keratoconic patients.

Keywords: Central corneal regularization, Corneal collagen cross-linking, Transepithelial, Excimer laser, Keratoconus

Background

Keratoconus is a disease in which a local failure of the corneal biomechanical strength results in abnormal corneal protrusion and thinning, leading to poor visual acuity and quality [1, 2]. Several approaches have been evaluated for correction of vision or for slowing down the progression of keratoconus. In addition to corneal transplantation, normally kept as the last resource, specialists' common practice includes the use of rigid contact lenses, implantation of intrastromal ring segments

and, in the last decade, corneal cross-linking (CXL). The goal of the last-mentioned approach has been to mostly stabilize the progression of the keratoectatic process, without specifically addressing or controlling vision [1, 3].

Previous studies concerning CXL alone demonstrated postoperative stability or small improvements in vision. In their > 3 years follow-up retrospective study, Raiskup-Wolf et al. [4], demonstrated an improvement in corrected distance visual acuity (CDVA) of 0.15 logMAR while Wittig-Silva et al. [5] in their prospective comparative study with > 3 years follow-up demonstrated an improvement of 0.09 logMAR in CDVA and of 0.15 logMAR in uncorrected distance visual acuity (UDVA).

* Correspondence: i.aslanides@emmetropia.gr

²Eye Hospital, Wenzhou Medical University, Wenzhou, China

⁴Emmetropia Mediterranean Eye Institute, Plateia Eleftherias 44, Heraklion, 71201 Crete, Greece

Full list of author information is available at the end of the article



In order to gain a better control of visual outcomes in addition to strengthening the cornea, CXL has been combined with other procedures such as laser vision correction, implantation of corneal ring segments, or use of phakic or aphakic intraocular lenses, thus improving eye optics. It seems that corneal surface ablation, performed in the same session as CXL or sequentially, has been the most popular of those procedures [1, 6, 7]. The combined treatment consisting of CXL preceded by a minimally invasive customized trans-epithelial corneal regularization seems to be a promising approach to freezing the keratoectatic process in an optically regularized cornea and achieving a potentially stable improvement of the quality of vision.

An innovative concept introduced by the iVis Suite customized excimer laser ablation treatment platform (iVis Technologies S. r. l., Taranto, Italy), named Central Corneal Regularization (CCR), was reported for the use in keratoconic corneas [6, 7]. The system uses topo/tomography-guided ablation to regularize the corneal shape by eliminating the higher order corneal morphological aberrations (HOCMA) within a very narrow central optical zone, while the treatment of the HOCMA towards the periphery gradually decreases within a large total ablation diameter. With this approach, the stromal tissue removal and the surgical invasiveness is kept to a minimum, while the customized “connecting refraction zone” instead of the traditional transition zone keeps the continuity of the corneal refractive power, with an aim of reducing the glare and haloes as well as the risk of regression. The current study retrospectively evaluates the clinical outcomes using the outlined approach combined with CXL performed right after the CCR, within the same surgical session.

Methods

This pilot study comprises 24 eyes (13 right and 11 left eyes) of retrospectively recruited 24 patients with keratoconus who underwent combined CCR and CXL, in a private eye clinic in Crete, Greece. Mean age was 28.92 years (SD 9.88, range 14 to 53).

Inclusion criteria comprised clinically diagnosed keratoconus with topographic changes consistent with moderate severity (Amsler-Krumeich stage I-II). All patients had visual acuity affected to the point where spectacles could not offer satisfactory results. Exclusion criteria consisted the presence of significant scars on the cornea, presence of other corneal disease, inflammation, or other disorders that could affect the final outcomes. The research was conducted according to the principles of the Declaration of Helsinki and ethical approval was granted by the institute’s review board.

Pre-operative assessment included uncorrected (UDVA) and corrected (CDVA) distant visual acuity, cycloplegic and non-cycloplegic manifest refraction, and slit lamp examination, including dilated fundoscopy and measurement of intraocular pressure. Scheimpflug-based Imaging corneal topo/tomography, obtained by Precisio (iVis Technologies S. r. l., Taranto, Italy), was used for a pre-operative diagnostic as the basis for custom surgery planning and pre- and postoperative structural and optical analysis, including the evaluation of HOCMA [6, 8]. For the measurement of the latter, a parameter describing optical regularity of the corneal surface, named HOCMA, was introduced by the manufacturer of the Precisio. The HOCMA are cumulatively all the refractive aberrations above the second order i.e., sphere and cylinder.

The measurement of the HOCMA provides an indication of the regularity of surface, which translates to the quality of vision of the patient: the higher the measured HOCMA, the worse the patient quality of vision. The HOCMA are clinically induced either secondary to complicated refractive, or other eye surgery, corneal injuries or post-keratitis scarring in stable corneas, or in unstable corneas due to ectatic disease. The HOCMA of the anterior corneal surface are calculated as the difference between the positive index of irregularity of the anterior corneal surface ($Ia+$) and the negative index of irregularity of the anterior corneal surface ($Ia-$), which are respectively the maximum and the minimum difference between the anterior corneal surface and the best fit toric surface calculated within the predefined domain (D), see enclosed picture (Fig. 1).

Surgical technique

All treatments were planned using the Corneal Interactive Programmed Topographic Ablation (CIPTA) software (iVis Technologies s. r. l., Taranto, Italy) in CCR mode [8, 9]. High definition anterior and posterior

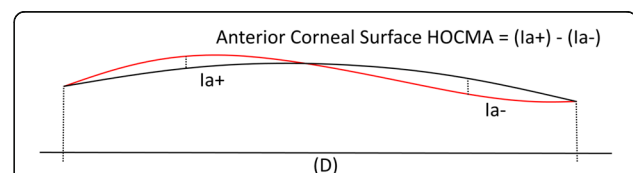


Fig. 1 Higher order corneal morphological aberrations (HOCMA) calculation. HOCMA – Morphological substrate for the anterior corneal surface optical aberrations above the second order, calculated with respect to the best fit toric surface within a predefined diameter. The HOCMA of the anterior corneal surface are calculated as the difference between the positive index of irregularity of the anterior corneal surface ($Ia+$) and the negative index of irregularity of the anterior corneal surface ($Ia-$), which are respectively the maximum and the minimum difference between the anterior corneal surface and the best fit toric surface calculated within the predefined domain (D)

corneal topography and pachymetry acquired by the Preciso were imported to CIPTA to design an ablation that aims to transform the preoperative irregular corneal morphology into a regular aconic shape of desired curvature, defined as the expected post-operative anterior corneal curvature according to the programmed treatment, and correct the corneal morphological irregularities and the eye's spherocylindrical refractive error. To achieve a minimal tissue removal from the biomechanically compromised cornea, a full regularization is aimed only within a narrow optical zone (1.0–1.5 mm in diameter), while the quality of the postoperative corneal optics is addressed by gradually fading custom ablation effect towards the periphery, within a total ablation zone of up to 9.8 mm in diameter. The large “connecting refractive zone” between the central optical zone and the untreated periphery features a smooth customized transition with a constant radial slope. The connecting zone is the surface between the refractive zone and the untouched corneal surface, designed with a constant slope in each radial direction, resulting in linear increase or decrease of curvature. All the treatments were planned to leave at least a 400 µm residual stromal bed.

Transepithelial single-step laser treatment, comprising a predefined ablation profile to achieve the epithelial removal and a customized component to achieve the corneal regularization, was executed with an uninterrupted ablation [7]. The predefined ablation profile to remove the epithelium was preprogrammed with a proprietary algorithm. The excimer laser used for the customized transepithelial treatment was the iRES (iVis Technologies S. r. l., Taranto, Italy), that has a small spot size of 0.65 mm and a frequency of up to 1000 Hz, delivered on the cornea. The laser employs a patented concept of constant frequency per area in order to prevent overheating due to its high frequency.

Prior to ablation, a semi-moist Merocell sponge (Medtronic Inc., USA) dipped in balanced salt solution (BSS) was applied on the corneal surface to avoid uneven wetting [1, 10]. After the laser ablation, the cornea was cooled with chilled BSS. Riboflavin drops (Medio-Cross D°, Medio-Haus Medizinprodukte GmbH, Neudorf, Germany) were used in all cases, every 2 min. The imbibition time of the riboflavin was 20 min. Corneal cross-linking was performed using a CCL-365 Vario (MLase AG, Germering, Germany) with power of 9 mW/cm² for 10 min, resulting in irradiance of 5.4 J/cm². Riboflavin drops were continued every 2 min during the CXL treatment. A drop of topical Ketorolac 0.5% and 1 drop of Ofloxacin 0.3% were instilled and a bandage contact lens was applied at the end of the surgery. Postoperative treatment consisted of Ofloxacin 0.3% drops q.i.d. until contact lens removal, Dexamethasone 0.1% drops q.i.d., and artificial tear drops q.i.d.

Postoperative assessment

Patients underwent routine postoperative assessment on the 1st, 3rd, 7th day and in the 1st, 3rd, 6th and 12th month. During the postoperative period from 1 month onwards, subjective refraction, slit-lamp biomicroscopy with grading of haze, intraocular pressure measurement and Preciso corneal topo/tomography were performed. Corneal haze was graded with an ordinal scale described by Fantes et al. [11]

Sample size

The determination of the minimum sample size needed to obtain a valid estimation of the clinical data in terms of CDVA ratio is performed using the following formula based on the desired precision (d) and on a Gaussian assumption [12].

$$\text{sample size } N = Z^2 \times \frac{\sigma^2}{d^2}$$

where:

Z = 1.96, the standardized normal deviation corresponding to the 95% confidence level;

σ^2 is the expected variance of the original data, which is estimated here below;

d is the desired precision of the deviation between the estimated value from the true value equal to 0.1.

The standard deviation can be estimated from the difference (h) between the highest and lowest values of the target parameter as $\sigma = 0.25 \times h$ for a symmetrical distribution shaped like an isosceles triangle.

The expected outcomes for the mean improvement in Corrected Distance Visual Acuity range from 1.0 to 1.6, equal to $h = 0.6$, where h is the highest value of the expected improvement in Corrected Distance Visual Acuity (1.6) minus the lowest value of the expected improvement in Corrected Distance Visual Acuity (1.0).

$$\sigma = 0.25 \times h = 0.25 \times 0.6 = 0.15$$

$$N = 1.96^2 \times (0.25 \times 0.6)^2 / 0.1^2 = 8.64$$

Considering an estimate of the follow up for the patients prudentially equal to 0.75, the number of cases to be enrolled for this study: N is equal to $8.64 \div 0.75 = 11.52 \approx 12$.

Statistical analysis

D'Agostino-Pearson normality test was performed to assess the normality of the dataset ($p > 0.05$). A one-way analysis of variance (ANOVA) with a significant level p of 0.05 was used to determine differences between pre-operative, 3 months post-operative, 6 months post-operative and 12 months post-operative. Tukey's multiple comparisons test was used to perform post hoc analysis. Statistically significant differences between the groups are indicated with (*) which represents a

p-value < 0.05, (**) which represents a p-value < 0.01, and (***) which represents a p-value < 0.001.

Results

24 eyes (13 right and 11 left eyes) of 24 patients meeting the inclusion criteria and signing the informed consent were included. There were 19 male and 5 female patients. Mean age was 28.92 years (SD 9.88, range 14 to 53). The average Max Ablation Depth (with epithelium) was 104.29 μm (SD 19.76, range 67.60 to 138.13). The average epithelium thickness is 50.92 μm (SD 3.39) and the average Max stromal ablation is 53.38 μm (SD 20.56). The preoperative epithelial profile maps were acquired using the Optovue OCT (Optovue, Fremont, CA, USA).

All the data presented a normal distribution ($p > 0.05$).

Mean preoperative spherical equivalent (SE) refractive error was -0.74 D (SD 1.17, range -3.35 to 0.82), while the cylinder error alone was -3.06 D (SD 1.83, range -0.50 to -8.29). The minimum mean pachymetry value and Kmax values before the treatment were 483.93 μm (SD 33.90, range 405 to 569) and 51.38 D (SD 3.29, range 45.65 to 58.14), respectively.

At 3 months postoperatively, the SE was -0.95 D (SD 2.31, range -10.85 to 1.73), while the cylinder's correction had a mean of -1.19 D (SD 0.79, range -2.80 to 0.82). In terms of pachymetry the post-operative measurements showed a mean thickness of 414.07 μm (SD 50.48, range 342 to 549) and the mean Kmax value dropped to 48.79 D (SD 2.98, range 43.99 to 55.45).

At 6 months postoperatively, the SE was -0.97 D (SD 1.00, range -4.59 to 0.25), while the cylinder's correction had a mean of -0.94 D (SD 0.56, range -2.01 to 0.00). In terms of pachymetry, the post-operative measurements showed a mean thickness of 431.78 μm (SD 49.45, range 357 to 532) and the mean Kmax value dropped to 48.85 D (SD 2.58, range 43.84 to 53.60).

At 12 months postoperatively, the SE was -1.05 D (SD 1.52, range -5.25 to 0.40), while the cylinder's correction had a mean of -1.04 D (SD 0.80, range 0.0 to -2.31). In terms of pachymetry, the post-operative measurements showed a mean thickness of 437.65 μm (SD 50.34, range 357 to 492) and the mean Kmax value dropped to 48.70 D (SD 2.58, range 44.02 to 53.04).

No statistically significant differences were detected among the groups for mean spherical equivalent (SE) refractive error (Fig. 2a). Comparing preoperative and postoperative data, a statistically significant reduction in terms of cylinder's correction, minimum mean pachymetry, and Kmax were detected. Considering the postoperative data, no statistical differences were observed among the 3 M postop, 6 M postop and 12 M postop (Figs. 2b-d).

Mean preoperative CDVA (logMAR) was 0.20 (SD 0.20, range 0.00 to 0.70). Mean CDVA (logMAR) at 3 months was 0.05 (SD 0.05, range 0.00 to 0.20). Mean CDVA (logMAR) at 6 months was 0.03 (SD 0.07, range -0.10 to 0.2). Mean CDVA (logMAR) at 12 months was 0.01 (SD 0.06, range -0.10 to 0.10).

The mean preoperative UDVA (logMAR) was 0.80 (SD 0.40, range 0.10 to 1.3). The mean post-operative UDVA (logMAR) at 3 months was 0.34 (SD 0.25, range 0.00 to 1.00). The mean post-operative UDVA (logMAR) at 6 months was 0.32 (SD 0.29, range 0.00 to 1.30). The mean post-operative UDVA (logMAR) at 12 months was 0.30 (SD 0.29, range 0.00 to 1.00).

Comparing preoperative and postoperative data, a statistically significant reduction in terms of mean CDVA and mean UDVA was detected while no statistically significant differences were detected among the 3 M postoperative, 6 M postoperative and 12 M postoperative timepoints (Figs. 2e, f).

In terms of safety, no eye lost lines of best corrected acuity. 3 eyes gained no extra lines of visual acuity and the remaining 21 had a mean improvement of 3.21 lines (SD 1.68, range 0 to 6).

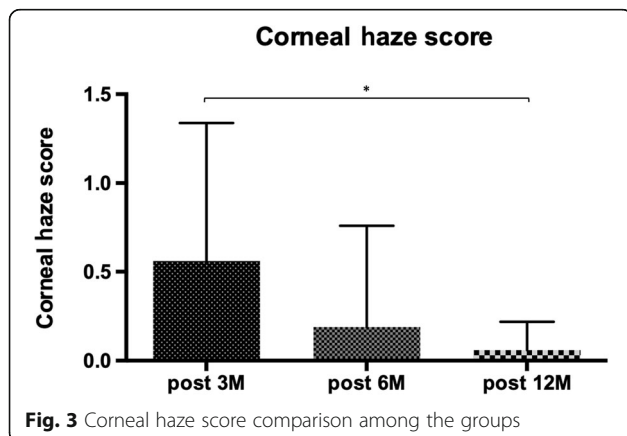
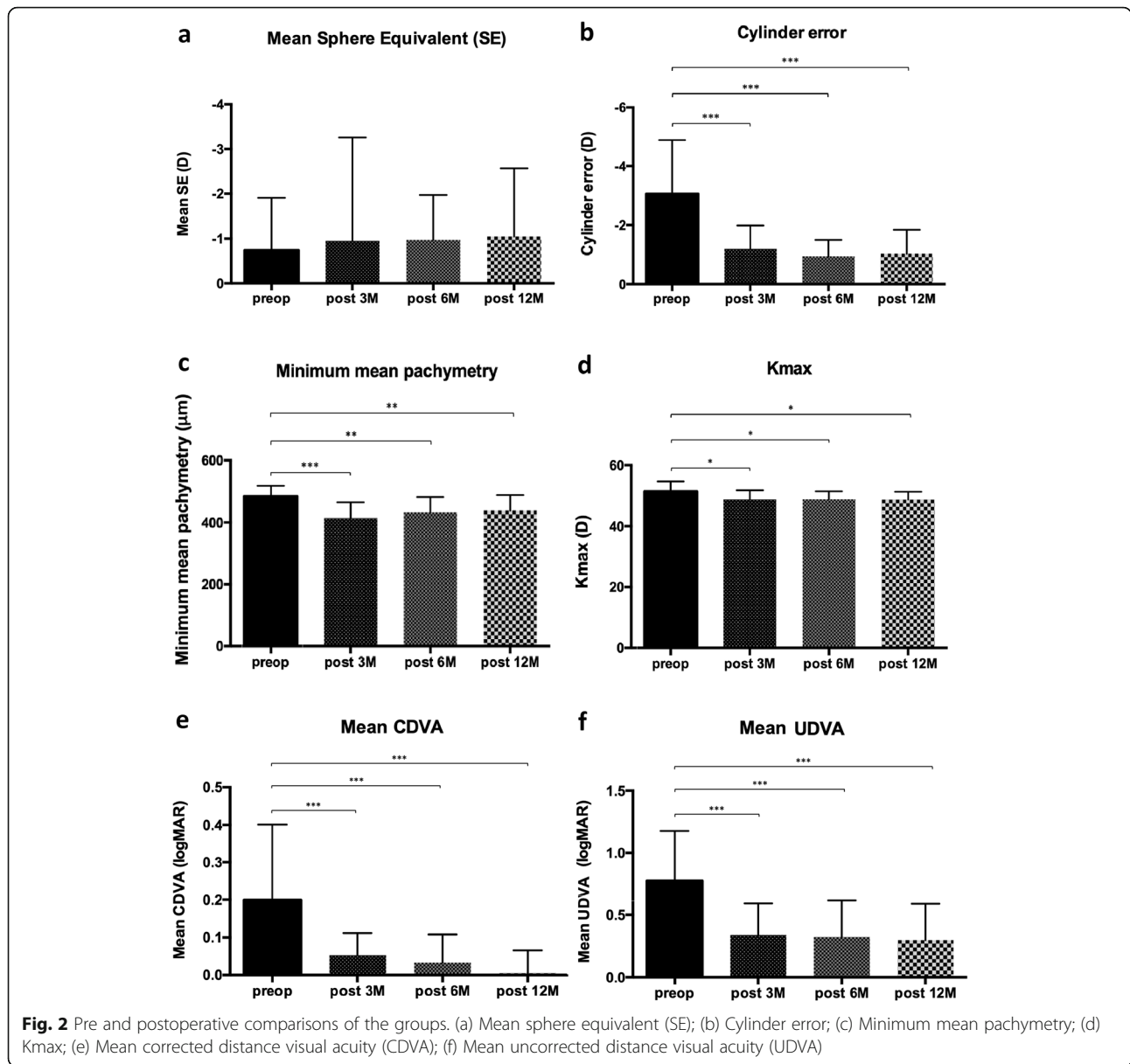
The corneal haze was clinically graded according to the Fantes scale [11]. The mean haze score in the 3rd, 6th and 12th month was 0.56 (SD 0.78), 0.19 (SD 0.57) and 0.06 (SD 0.16), respectively. The detected mean haze score was statistically lower at 12 M postoperatively with respect to 3 M postoperatively showing that ultimately there was no opacity that could affect the patients' visual acuity (Fig. 3).

Considering the mean anterior HOCMA analysis at 2 mm, a statistically significant reduction between preoperative and postoperative (3 M, 6 M and 12 M) was detected. In particular, the HOCMA at 2 mm were reduced by a factor of 3 after the surgery (Fig. 4a). The same trend was detected evaluating the mean anterior HOCMA at 3.5 mm. In this case, the HOCMA at 2 mm were reduced by a factor of 2 (Fig. 4b).

A similar trend was detected for mean anterior HOCMA at 5 mm and 6 mm. Considering the mean anterior HOCMA analysis at 5 mm, a statistically significant reduction by a factor of 2 between preoperative and postoperative (3 M, 6 M and 12 M) was detected (Fig. 4c). A similar trend was observed when we evaluated the mean anterior HOCMA at 6 mm. In this case, the HOCMA at 2 mm were reduced by a factor of 3 (Fig. 4d).

Discussion

This small series study assesses an approach that combines corneal customized transepithelial therapeutic ablation to treat the irregular corneal optics and accelerated cross-linking technique to strengthen the corneal tissue and stop the progression of keratoconus.



Stiles–Crawford effect teaches that the most relevant portion of the cornea of interest for the distinct vision is the central 1.00 mm [13]. For this reason, a small central optical zone (1.0–1.5 mm) was selected to minimize corneal tissue ablation. In parallel to that, a customized connecting refractive zone with a constant radial slope and the continuity of the refractive power was planned with an aim to minimize the risk for glare and haloes as well as the risk for regression.

Different studies demonstrated that the combination of topography-guided photorefractive keratectomy (tPRK) and CXL procedures has the potential to improve both visual acuity and corneal stability [14, 15]. Kymionis et al. demonstrated the positive outcomes of combined tPRK with CXL in a noncomparative prospective cohort of

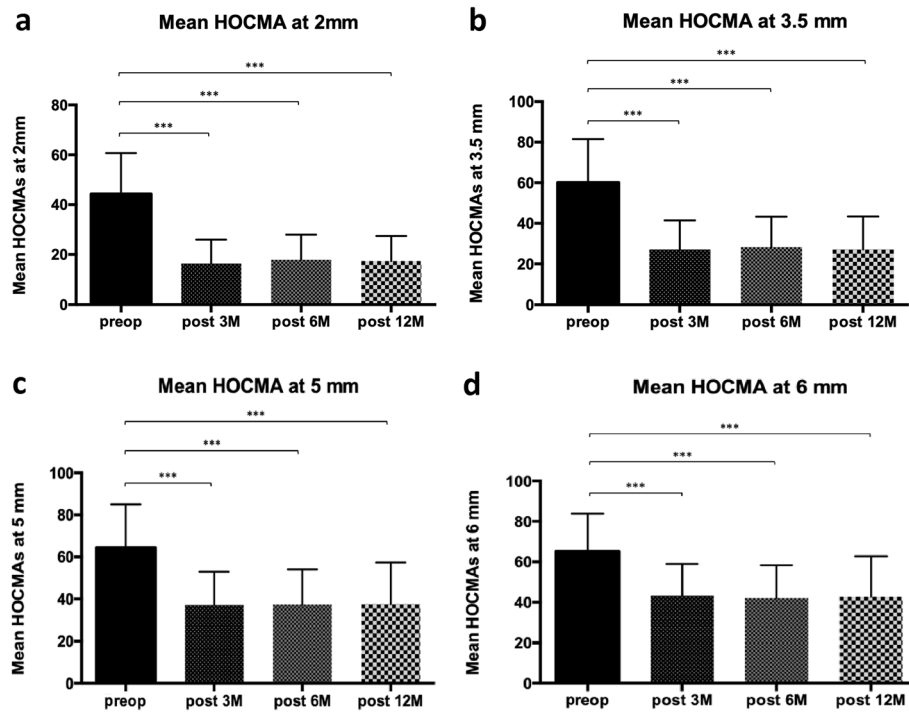


Fig. 4 Mean higher order corneal morphological aberrations (HOCMA) among the groups at different diameters. (a) HOCMA at 2 mm; (b) HOCMA at 3.5 mm; (c) HOCMA at 5 mm; (d) HOCMA at 6 mm

patients with keratoconus and ectasia occurring after LASIK showing a significant improvement in UDVA, CDVA and stability [15]. Alessio et al. performed a prospective comparative study of tPRK with an excimer laser and CXL versus CXL alone and found higher improvement in visual acuity in the group of patients treated with combined customized treatment in comparison with CXL alone [16]. Kanellopoulos demonstrated the positive outcomes of the combination of surface ablation with CXL in a single case report of a patient treated with CXL followed by a tPRK procedure after 1 year [17]. In addition, Kanellopoulos et al. published a retrospective comparison of same-day simultaneous collagen CXL and tPRK versus CXL sequentially followed by tPRK after 6 months for treatment of keratoconus. They reported a better average improvement in UDVA in the same-day group with respect to the sequential group [18]. Kontadakis et al. prospectively compared the topographic and refractive results in patients treated with simultaneous tPRK and CXL with those patients treated with CXL alone demonstrating that the combined technique improved the vision of the treated patients in comparison with CXL alone while similar results in terms of postoperative stability were detected [14].

Epithelial removal by use of the concept of transepithelial PTK was chosen to take advantage of the smoothing effect that the epithelial remodeling has on the underlying corneal stroma. Due to the uneven thickness of the epithelium covering the irregular

stromal surface in keratoconus, the predefined ablation profile will in addition to the epithelium, ablate the parts of the protruding stroma, where the epithelial thickness is below the preset ablation depth. This approach has been widely reported to be successful and advantageous to the mechanical or chemical epithelial removal [19, 20]. The current approach went a step further by regularizing the corneal surface beyond the effect of the smoothing effect of the epithelial remodeling, while keeping the low stromal ablation depth and volume. Good results in treatment of keratoconus with the current system using topography-guided ablation with larger optical zones and combined with CXL has been shown earlier [7], but the stromal ablation depth and volume were necessarily higher with that approach [7]. In order to further decrease the stromal tissue consumption, pre-operative epithelial mapping may be used. Knowing that the epithelial thickness is generally lower in keratoconus than in normal virgin eyes [21], using the real thickness instead of the manufacturer's proprietary algorithm in the programming of the treatment could spare a certain additional amount of stromal tissue. In addition, the results obtained in this study are comparable with the ones presented by Kontadakis et al. [14] and Alessio et al. [16] in terms of mean UDVA and mean CDVA demonstrating that the combined CCR and CXL technique proposed in this study

can offer a considerable and effective improvement for keratoconic patients.

Conclusions

In conclusion, we believe that CCR combined with CXL offers promising results and is an effective treatment in keratoconic patients with contact lens intolerance.

Acknowledgements

Not applicable.

Authors' contributions

Concept and design (CD), data acquisition (DA), data analysis/interpretation (DI), drafting manuscript (DM), statistical analysis (SA), critical revision (CR) of manuscript, supervision (SV). Giulio Mulè – CD, DA, DI, SA, CR, SV, Shihao Chen – DI, CR, SV, Jia Zhang – DM, Wen Zhou – DI, CR, SV, Vasileios Selimis – DI, DM, SA, CR, SV, Aleksandar Stojanovic – DI, DM, CR, SV, Ioannis Aslanides – CD, DA, DI, DM, SA, CR, SV. All authors read and approved the final manuscript.

Funding

Not applicable.

Availability of data and materials

The datasets used and/or analyzed during the current study are available from the corresponding author on reasonable request.

Ethics approval and consent to participate

All patients gave their informed consent for their anonymized data to be submitted for audit and publication. The Emmetropia Mediterranean Eye Institute Ethics Committee approved this study as an audit study and gave it the following reference number: RS003/2019.

Consent for publication

Not applicable.

Competing interests

The authors declare that they have no competing interests.

Author details

¹iVis Trento Center, San Camillo Hospital, Trento, Italy. ²Eye Hospital, Wenzhou Medical University, Wenzhou, China. ³SynsLaser Kirurgi AS, Skippergata 7, Tromsø, Norway. ⁴Emmetropia Mediterranean Eye Institute, Plateia Eleftherias 44, Heraklion, 71201 Crete, Greece.

Received: 27 April 2019 Accepted: 7 November 2019

Published online: 16 December 2019

References

- Mukherjee AN, Selimis V, Aslanides I. Transepithelial photorefractive keratectomy with crosslinking for keratoconus. *Open Ophthalmol J*. 2013;18(7):63–8.
- Kolli S, Aslanides IM. Safety and efficacy of collagen crosslinking for the treatment of keratoconus. *Expert Opin Drug Saf*. 2010;9(6):949–57.
- Wollensak G, Spoerl E, Seiler T. Riboflavin/ultraviolet-a-induced collagen crosslinking for the treatment of keratoconus. *Am J Ophthalmol*. 2003;135(5):620–7.
- Raiskup-Wolf F, Hoyer A, Spoerl E, Pillunat LE. Collagen crosslinking with riboflavin and ultraviolet-A light in keratoconus: long-term results. *J Cataract Refract Surg*. 2008;34(5):796–801.
- Wittig-Silva C, Chan E, Islam FM, Wu T, Whiting M, Snibson GR. A randomized, controlled trial of corneal collagen cross-linking in progressive keratoconus: three-year results. *Ophthalmology*. 2014;121(4):812–21.
- Kaufmann C, Bochmann F, Baenninger P, Thiel MA. Central corneal regularization—optimization of uncorrected visual acuity in keratoconus patients. *Klin Monatsbl Augenheilkd*. 2013;230(4):333–6.
- Stojanovic A, Zhang J, Chen X, Nitter T, Chen S, Wang Q. Topography-guided transepithelial surface ablation followed by corneal collagen cross-linking performed in a single combined procedure for the treatment of keratoconus and pellucid marginal degeneration. *J Refract Surg*. 2010;26(2):145–52.
- Stojanovic A, Chen X. Preciso surgical tomographer. In: Ming W, editor. *Corneal topography: a guide for clinical application in the wavefront era*. Thorofare: Slack Inc.; 2012. p. 126–30.
- Alessio G, Boscia F, La Tegola MG, Sborgia C. Topography-driven photorefractive keratectomy: results of corneal interactive programmed topographic ablation software. *Ophthalmology*. 2000;107(8):1578–87.
- Aslanides IM, Padroni S, Arba Mosquera S, Ioannides A, Mukherjee A. Comparison of single-step reverse transepithelial all-surface laser ablation (ASLA) to alcohol-assisted photorefractive keratectomy. *Clin Ophthalmol*. 2012;6:973–80.
- Fantes FE, Hanna KD, Waring GO 3rd, Pouliquen Y, Thompson KP, Savoldelli M. Wound healing after excimer laser keratomileusis (photorefractive keratectomy) in monkeys. *Arch Ophthalmol*. 1990;108(5):665–75.
- Checklist of information usually submitted in an investigational device exemption (IDE) application for refractive surgery lasers. *Ophthalmic Devices Advisory Panel, Food and Drug Administration*. *J Refract Surg*. 1997;13(6):579–88.
- Westheimer G. Directional sensitivity of the retina: 75 years of Stiles-Crawford effect. *Proc Biol Sci*. 2008;275(1653):2777–86.
- Kontadakis GA, Kankariya VP, Tsoulnaras K, Pallikaris AI, Plaka A, Kymionis GD. Long-term comparison of simultaneous topography-guided photorefractive keratectomy followed by corneal cross-linking versus corneal cross-linking alone. *Ophthalmology*. 2016;123(5):974–83.
- Kymionis GD, Kontadakis GA, Kounis GA, Portaliou DM, Karavitaki AE, Magarakis M, et al. Simultaneous topography-guided PRK followed by corneal collagen cross-linking for keratoconus. *J Refract Surg*. 2009;25(9):S807–11.
- Alessio G, L'abbate M, Sborgia C, La Tegola MG. Photorefractive keratectomy followed by cross-linking versus crosslinking alone for management of progressive keratoconus: two-year follow-up. *Am J Ophthalmol*. 2013;155(1):54–65.e1.
- Kanellopoulos AJ, Binder PS. Collagen cross-linking (CCL) with sequential topography-guided PRK: a temporizing alternative for keratoconus to penetrating keratoplasty. *Cornea*. 2007;26(7):891–5.
- Kanellopoulos AJ. Comparison of sequential vs same-day simultaneous collagen cross-linking and topography-guided PRK for treatment of keratoconus. *J Refract Surg*. 2009;25(9):S812–8.
- Kapasi M, Dhaliwal A, Mintsoulis G, Jackson WB, Baig K. Long-term results of phototherapeutic keratectomy versus mechanical epithelial removal followed by corneal collagen cross-linking for keratoconus. *Cornea*. 2016;35(2):157–61.
- Chen X, Stojanovic A, Xu Y, Zhou W, Raeder S, Enayati S, et al. Medium- to long-term results of corneal cross-linking for keratoconus using phototherapeutic keratectomy for epithelial removal and partial stromal ablation. *J Refract Surg*. 2017;33(7):488–95.
- Reinstein DZ, Gobbe M, Archer TJ, Silverman RH, Coleman DJ. Epithelial, stromal, and total corneal thickness in keratoconus: three-dimensional display with Artemis very-high frequency digital ultrasound. *J Refract Surg*. 2010;26(4):259–71.

Ready to submit your research? Choose BMC and benefit from:

- fast, convenient online submission
- thorough peer review by experienced researchers in your field
- rapid publication on acceptance
- support for research data, including large and complex data types
- gold Open Access which fosters wider collaboration and increased citations
- maximum visibility for your research: over 100M website views per year

At BMC, research is always in progress.

Learn more biomedcentral.com/submissions

